



Automated Bladder Volume

A valuable tool in the Emergency Department to help guide treatment and intervention decisions at the bedside.

A Case Study by:
Michael Coulthard, MD

“Is complaint of urinary retention truly a bladder outlet obstruction?”

Introduction

Urinary retention, though often chronic, can be an emergency condition requiring immediate medical attention. Quick recognition of the cause and timely bladder decompression are of utmost importance to prevent morbidity and relieve pain. Acute urinary retention can be caused by a variety of conditions, and some causes can lead to permanent impairment if not dealt with promptly.¹

Approximately 10% of men in their 70s and 33% of men in their 80s report at least one episode of acute urinary retention.² As a result, limited pelvic exams are among the most common CPT codes claimed by Emergency Department (ED) clinicians. Point-of-care ultrasound (POCUS) enables quick identification of whether or not bladder catheterization is necessary, directly improving speed of bladder decompression, the definitive treatment for acute urinary retention. This can immediately relieve pain and has significant potential operational advantages, by saving institutional money on unnecessary testing, and improving the patient's satisfaction scores regarding their ED experience.³

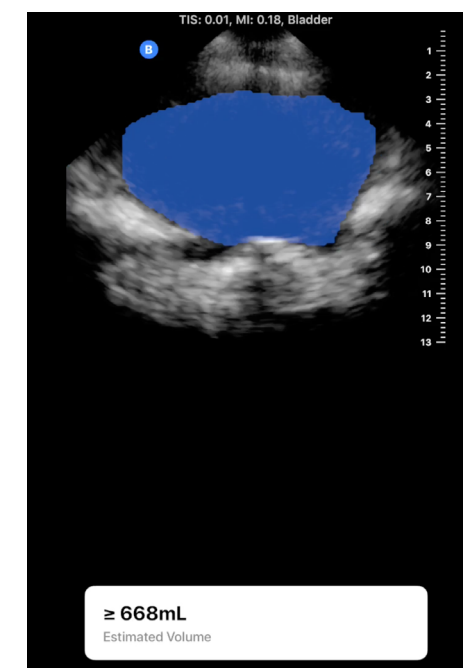
Case History

Presented below are two patients each presenting with a complaint of urinary retention. The first has a history of one non-functional kidney and suspected kidney stone. The other patient has a history of benign prostatic hypertrophy. With POCUS, one can easily determine that the first patient has an empty bladder and a Foley catheter is not necessary (Fig.1), while the second patient has a distended bladder and is in need of a Foley catheter (Fig 2). Many EDs have a bladder scanner available, but those do not provide visualization of the bladder, and are often performed after the initial evaluation, when an order for bladder volume measurement has been placed. This has the potential to delay treatment and can result in a longer duration of discomfort for the patient. With the Butterfly iQ, not only can one quickly scan the patient during the evaluation, but one can also obtain a measurement of bladder volume, further supporting any invasive procedures.

Fig 1. Limited pelvis POCUS exam reveals an empty bladder.

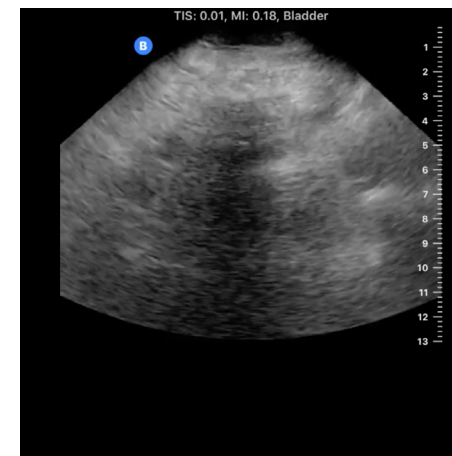

Fig 2. Automated volume measurement with Butterfly iQ reveals a distended bladder of over 600mls.



References

1. <https://pubmed.ncbi.nlm.nih.gov/24804332/>
2. Data provided by Medscape
3. <https://www.emra.org/emresident/article/acute-urinary-retention-in-the-emergency-department/>